



## Gliomatosis Cerebri (GC), Presentation, Management & Prognostic Overview

Raad Ahmed Hussein\*, Muhammed Hameed Faeadh Al-Jumaily, Rana Hani Mohammed Ali Al-Shaikh Hamed

<sup>1</sup>. Aliraqia University. College of Medicine. Department of Internal Medicine. Neurology Unit./Iraq.

<sup>2</sup>. Aliraqia University. College of Medicine. Department of Surgery. Neurosurgery Unit/Iraq.

<sup>3</sup>. Aliraqia University. College of Medicine. Department of Pharmacology/Iraq.

\*Corresponding Author: Raad Ahmed Hussein

### Abstract

Gliomatosis cerebri (GC) is a rare, infiltrating glioma of brain & spinal cord. It affects children, adult & elder age groups. Objective: To have an overview on the clinical presentation, management, prognosis & survival period of patients with GC. Material & methods: We retrospectively studied the clinical presentation & management and prognosis in 14 patients of gliomatosis cerebri between 2013 and 2016. The presentation is that of raised ICP, focal neurodeficit & epilepsy. Results: All patients treated with radiotherapy, followed in few cases by chemotherapy. The survival time was not more than 2 years in all cases. The diagnosis is based on radiological MRI studies & histopathology. Treatment: Surgical treatment is not usual option due to wide spread neuraxis involvement. Radiation therapy & chemotherapy may give some survival benefit. The outcome of the disease & the prognosis is poor & the survival period not exceeds 24 months with the best combined chemotherapy & radiotherapy.

**Keywords:** *Multiple malignant glioma. Gliomatosis cerebri.*

### Introduction

Gliomatosis cerebri (GC): is a diffuse, infiltrating astrocytoma that invades almost all of the cerebral hemispheres and brainstem. Low-grade areas of anaplasia and glioblastoma may also occur and may present as focal mass most frequently in 1st 2 decades [1]. GC is a rare, diffusely infiltrating glial brain tumor. Prognosis is poor; with 26-52% surviving less than a year from symptom onset [2, 3].

It is rare diffuse gliomas of multiple lobes of the brain. There may be discordance between clinical & radiological findings, as it may be clinically silent while it appears as a very extensive process radiologically [4]. GC is a grand manifestation of extensively infiltrative diffuse glioma involving at least three cerebral lobes.

The rarity of the disease, lack of understanding tumor biology, variation across histopathological grading, variability in patient outcomes, and the lack of durable

response to therapies are major obstacles toward establishing standard treatments [5]. GC is classified as primary or secondary GC [6, 7].

Primary GC is extensive CNS involvement at initial presentation [8]. It is further sub classified as type I (classic) when no obvious mass is present, or type II, where a diffuse infiltrative pattern coexists with an associated tumor mass [3]. Secondary GC is progressive extension observed over follow up of initial local diffuse glioma [8]. It is infiltrative spread of tumor cells from a previously diagnosed glioma and is frequently associated with prior radiation or antiangiogenic therapy [3, 6].

### Aim of Study

To have an overview on the clinical presentation, management, prognosis & survival period of patients with GC.

## Patients & Methods

This is a retrospective study that had been done for 14 patients with Gliomatosis cerebri collected in Al Shaik Zaed hospital & Ibn Al Haitham Hospital in Jordan-Amman, between January 2013 and February 2016.

The diagnosis was achieved based on the clinical history & examination & radiological MRI studies followed by stereotactic based histopathological diagnosis. After the histopathological diagnosis, all the patients received symptomatic intracranial pressure (ICP) reducing treatment with antiepileptic medication for patients with epilepsy, followed by conventional whole neuraxis radiotherapy.

Four patients received chemotherapy. Two patients had been complicated by obstructive hydrocephalus & treated with temporary external ventriculostomy. The following up period was over two years. All the patients died at the end of the 2<sup>nd</sup> year.

## Results

In this study, we have 14 patients, 3 patients were females and 11 were males. The patients Age ranged from 6 years-75 years, where 5 of them were between 50-60 years

and 7 of them were more than 60 years & two were children less than 10 years. All the patients presented with headache, 2 of them with epilepsy, 8 of them with focal neurology including mental & behavioral dysfunction, hemiparesis & cranial nerve dysfunction. The karnofsky performance score at time of presentation ranged from 50-90.

Neurological Examination included visual field deficit & papilledema in 8 cases, cranial nerve deficit in 3 patients, facial palsy in 2 patients & extraocular muscle dysfunction in 1 patient. After the radiological (MRI) & histopathological diagnosis, all the patients received symptomatic ICP reducing measures with antiepileptic medication for those who developed epilepsy, followed by a conventional whole neuraxis radiotherapy (50 Gray), 4 patients received chemotherapy with temozolomide 75 mg/m<sup>2</sup>.

Two patients had been complicated by obstructive hydrocephalus & treated with temporary external ventriculostomy drain. One patient died within one month of presentation and diagnosis before radiation therapy. The following up period was over two years. All the patients died at the end of the 2<sup>nd</sup> year.

**Table 1: Age & sex distribution**

Age in years.	Female	Male	Total
Adult 50 -60	2	3	5 (35.7%)
Elder ≥ 60	1	6	7 (50%)
Children ≤ 10	0	2	2 (14.3%)
<b>Total</b>	<b>3 (21.4%)</b>	<b>11 (78.6%)</b>	<b>14 (100%)</b>

**Table 2: Clinical presentation**

Presentation	No.
Headache	14 (100%)
Focal neurodeficit	8 (57.1%)
Epilepsy	2 (14.3%)

**Table 3: Treatment & Prognosis**

Therapy	
Radiotherapy (RRx.)	13 (93%)
RRx. & ChemoRx.	4 (28.6%)
Palliative surgery	2 (14.3%)

**Table 4: mortality & survival**

Mortality in 1 <sup>st</sup> year	4 (28.6%)
Mortality in 2 <sup>nd</sup> year	10 (71.4%)
Mortality after 2 years	14 (100%)

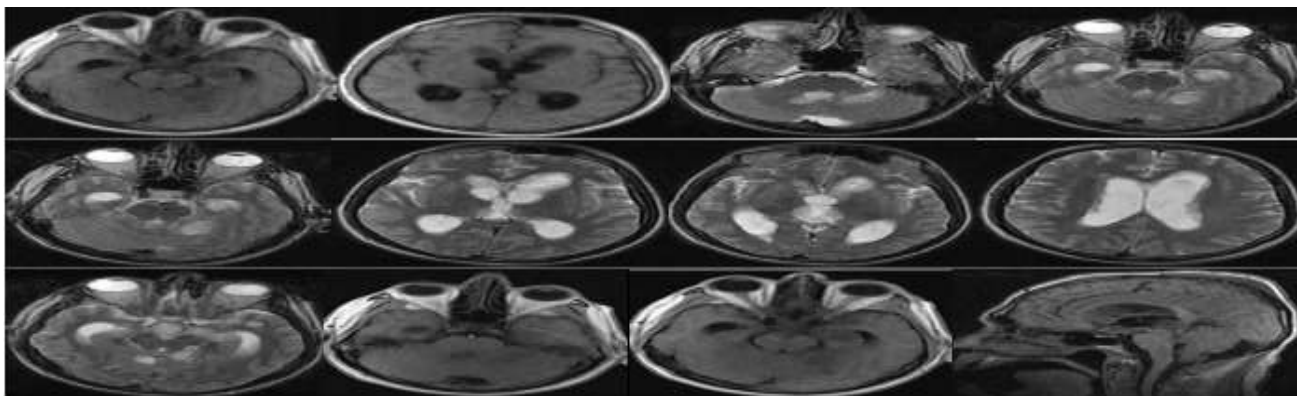


Figure 1: Multiple axial & sagittal T1/T2 WI brain MRI of 60 year old patient with GC

## Discussion

Gliomatosis cerebri (GC) is a rare brain tumor. It is a grand manifestation of extensively infiltrative diffuse glioma involving at least three cerebral lobes [5]. The rarity of the disease, lack of understanding tumor biology, variation across histopathological grading, variability in patient outcomes, and the lack of durable response to therapies are major obstacles toward establishing standard treatments [5].

GC is diffuse infiltrating glioma involving the supratentorial compartment, posterior fossa, or even intraspinal parenchyma [9]. In this study all of the cases presented with supratentorial GC. However we have 2 cases that have, in addition, posterior fossa & spinal glial carcinomatosis.

We have 78.5% of cases were males & 21.5% were females. These results are agreeing with the sex distribution of the series of Taillibert S et al., Kim DG, et al. & Vates GE et al [7, 10, 11]. The disease occurred in all age groups but was most common in the fifth decade with a second peak in the second decade [12].

In our study, 35.7% of cases were in the fifth decade & 50% of cases were older than 60 years & only 14.3% of cases were children less than 10 years. The clinical presentations in our patients were headache in all 14 patients (100%), epilepsy in 2 patients (14.3%), focal neurodeficit like mental/behavioral dysfunction, hemiparesis & lower cranial nerve dysfunction in 8 patients (57%).

Neurological Examination included visual field deficit & papilledema in 8 cases (57%), cranial nerve deficit in 3 patients (21.4%), facial palsy in 2 patients (14.3%) & extraocular muscle dysfunction in 1 patient

(7%). In the study of Vates GE. et al., the clinical presentation is subtle and nonspecific, reflects the diffuse neuronal disruption caused by the disease manifesting as seizures, focal neurological deficits, memory loss, and other higher mental functions impairment [11].

Ghostine S. et al., concluded that the radiological diagnosis was difficult & the brain CT may be normal or shows subtle squashing of the ventricles or hypodensity or diffuse cerebral edema. In MRI of the brain, T2-weighted images and FLAIR images show heterogeneous hyper intensities with no uptake of contrast, appearing similar to CNS inflammatory diseases, vasculitis, leukoencephalopathies or venous infarcts. The relative preservation of the blood-brain barrier is thought to be the reason for nonenhancement of contrast [13].

The General imaging differential diagnosis of GC include: [14] a. progressive multifocal leukoencephalopathy in an immunocompromised patient. b. multifocal / multi centric glioblastoma. C. primary CNS lymphoma which usually vividly enhancing. D. encephalitis. We agreed with Ghostine S. et al. study, where all our cases demonstrated hyperintense lesions on T2 WI and hypointense on T1 WI with variable contrast enhancement. In our cases, the histopathological results are characterized by the presence of necrotizing tissues surrounded by anaplastic cells as well as hyperplastic blood vessels with microvascular invasion.

In the study of Kim DG et al., the tumor cells diffusely infiltrate white and gray matter and sometimes exhibited the perineuronal, perivascular or subpial tumor cell collections.

The infiltrating cells showed variation from small cells with little cytoplasm to cells with moderate cytoplasm and the nuclei from elongated, oval to round [10]. The real pathological lesion demonstrated at autopsy is always wider than the lesion shown in MRI or positron emission tomography [10]. In the study of Bernsen H. et al., the Angiogenesis was absent in the gliomatosis cerebri, suggesting that tumor growth in these neoplasms is supported by coaptation of the existing vasculature and not by the formation of new vessels [15].

Apart from one patient, in our study, who died after few weeks from the diagnosis due to raised ICP & respiratory failure, all the other patients received conventional whole neuraxis radiotherapy with a median dose of 50 Gray, we have 4 patients received chemotherapy with temozolomide 75 mg/m<sup>2</sup> & all of them survived beyond the first year. Two patients had been complicated by obstructive hydrocephalus & treated with temporary external ventriculostomy.

The following up period was over two years. All the patients died at the end of the 2<sup>nd</sup> year, 4 patients of them died at the first year. In the study of Elshaikh et al., 8 of 12 patients received only radiation treatment. The clinical and radiological findings improved in 3 patients, stabilized in 3 patients, and deteriorated in 2 patients. Median survival was 11.4 months, and the results concluded that radiation alone was

not sufficient, and, therefore, more aggressive therapy may be needed [16]. In the retrospective study of Perkins et al. on 30 patients, the conclusion was that Radiotherapy is effective against gliomatosis cerebri. Patients who are young and have a nonglioblastoma tumor of histologic subtype perform more favorably. Median survival was 18 months [17].

Levin N et al. instituted that patients with GC receiving initial chemotherapy having disease progression-free survival of 12 months, and this concluded that temozolomide chemotherapy can be used initially, and radiotherapy can be deferred until the disease progression is documented. [18] Taillibert S. et al., instituted that in GC, the Oligodendroglial variant is more common in males and has a better prognosis while the astrocytic variant carries worst prognosis. Median survival is least in astrocytic tumors around 11 months, and the oligodendroglial variant has survival up to 36 months & the median survival is 18.5 months [7] Poor performance scores at presentation have uniformly predicted bad prognosis even in the presence of favorable histology [7].

## Conclusion

GC is a diffuse infiltrating high grade poor prognostic glioma. It is diagnosed by radiological & histopathological study. Surgical treatment is of limited role & the treatment with radiotherapy & chemotherapy may give some benefit in the survival rate.

## References

1. Mark S (2016) Greenberg. Handbook of neurosurgery. 8<sup>th</sup> Edition, 36 (7): 619.
2. Herrlinger U, Jones DT, Glas M, Hattungen E, Gramatzki D, Stuplich M, et al (2015) Gliomatosis cerebri: no evidence for a separate brain tumor entity. *Acta Neuropathol.*, 131(2):309-19.10.1007/s00401-015-1495-z.
3. Jennings MT, Frenchman M, Shehab T, Johnson MD, Creasy J, LaPorte K, et al (1995) Gliomatosis cerebri presenting as intractable epilepsy during early childhood. *J. Child. Neurol.*, 10(1):37-45.10.1177/088307389501000111.
4. David N Louis, Hiroko Ohgaki, Otmar D Wiestler, Wbster K Cavenee (2016) International Agency for Research on Cancer, WHO Classification of Tumours of the Central Nervous System, Revision ISBN: 9789283244929.
5. Surabhi Ranjan<sup>1</sup>, Katherine E Warren, Gliomatosis Cerebri (2017) Current Understanding and Controversies, 7. doi: 10.3389/fonc.2017.00165.
6. Sanson M, Cartalat-Carel S, Taillibert S, Napolitano M, Djafari L, Cougnard J, et al (2004) Initial chemotherapy in gliomatosis cerebri. *Neurology*, 63(2):270-5.10.1212/01.WNL.0000129985.39973.E4.
7. Taillibert S, Chodkiewicz C, Laigle-Donadey F, Napolitano M, Cartalat-Carel S, Sanson M (2006) Gliomatosis cerebri: a review of 296 cases from the ANOCEF database and the literature. *J. Neurooncol.*, 76(2):201-5.10.1007/s11060-005-5263-0.

8. Jaime Gasco, Remi Nader (2013) The essential neurosurgery companion. Chapter 35 1.2.4. Brain tumor, 416.
9. Fallentin E, Skriver E, Herning M, Broholm H (1997) Gliomatosis cerebri-An appropriate diagnosis?. Case reports. Acta. Radiol., 38:381-90.
10. Kim DG, Yang HJ, Park IA, Chi JG, Jung HW, Han DH, et al (1998) Gliomatosis cerebri: Clinical features, treatment, and prognosis. Acta Neurochir (Wien) 140:755-62.
11. Vates GE, Chang S, Lamborn KR, Prados M, Berger MS (2003) Gliomatosis cerebri: A review of 22 cases. Neurosurgery, 53:261-71.
12. Kandler RH, Smith CM, Broome JC, Davies-Jones GA (1991) Gliomatosis cerebri: A clinical, radiological and pathological report of four cases. Br J. Neurosurg., 5:187-93.
13. Ghostine S, Raghavan R, Michelson D, Holshouser B, Tong K (2007) Gliomatosis cerebri mimicking Rasmussen encephalitis. Case report. J. Neurosurg., 107:143-6.
14. Castillo M Neuroradiology Companion: Methods, Guidelines, and Imaging Fundamentals. LWW. ISBN: 1451111754.
15. Bernsen H, Van der Laak J, Küsters B, Van der Ven A, Wesseling P (2005) Gliomatosis cerebri: Quantitative proof of vessel recruitment by cooptation instead of angiogenesis. J. Neurosurg., 103:702-6.
16. Elshaikh MA, Stevens GH, Peereboom DM, Cohen BH, Prayson RA, Lee SY, et al (2002) Gliomatosis cerebri: Treatment results with radiotherapy alone. Cancer, 95: 2027-31.
17. Perkins GH, Schomer DF, Fuller GN, Allen PK, Maor MH (2003) Gliomatosis cerebri: Improved outcome with radiotherapy. Int. J. Radiat. Oncol. Biol. Phys., 56:1137-46.
18. Levin N, Gomori JM, Siegal T (2004) Chemotherapy as initial treatment in gliomatosis cerebri: Results with temozolomide. Neurology, 63:354-6.