



Congenital Pseudoarthrosis Tibia (CPT) Performed Free Vascularized Fibular Graft: A Case Report

Muhammad Bayu Wicaksono^{1*}, Heri Suroto², IDN Suci Anindya³, Meirizal⁴

^{1.} *Departement Orthopaedic dan Traumatology, Dr. Sardjito General Hospital / Faculty of Medicine Gadjah Mada University, Yogyakarta, Indonesia*

^{2.} *Departement Orthopaedic dan Traumatology, Airlangga University, Surabaya, Indonesia*

^{3.} *Departement Orthopaedic dan Traumatology, Dr. Soeradji Tirtonegoro General Hospital, Klaten, Indonesia*

^{4.} *Departement Orthopaedic dan Traumatology, Dr. Sardjito General Hospital / Faculty of Medicine Gadjah Mada University, Yogyakarta, Indonesia*

***Corresponding Author: Muhammad Bayu Wicaksono**

Abstract

Congenital pseudarthrosis of the tibia (CPT) remains one of the most challenging problems confronting the orthopaedic surgeon. The operative results are frequently less than successful; many cases require several surgical procedures, and a significant number of them ending in amputation. The purpose of this study was to access the surgical results, complications, secondary procedures, and long-term results of free vascularized fibular graft (FVFG). We reported a case of a 5 years old boy complained unable to walk, was diagnosed as Congenital Pseudarthrosis of the left tibia. The patient had been doing several operation procedure, finally performed FVFG. After 5 months follow up, ORIF with intramedullary Kirschner wire provided stability, and acceptable alignment resulted in bony union. However, even achieving union of pseudarthrosis is not enough for the resolution of the disease. This is only half of the problem; the other half is to maintain union.

Keywords: *Congenital pseudoarthrosis tibia, Free Vascularized Fibular graft.*

Introduction

Congenital pseudoarthrosis of the tibia is a rare disease with reported incidence ranging from 1:140000 to 1:250000 births of neonates. It is characterized by segmental osseous weakness resulting in deformities of the bone and spontaneous fractures which progresses to a non-union tibia. The etiology is unknown. In 50% of the cases it is associated with neurofibromatosis. The pathologic process of the disorder is the growth of abnormal fibromatosis like tissue either within the periosteum (dysplastic type) or both.

Management of Congenital Pseudarthrosis of the left tibia is one of the most challenging problems in pediatric orthopedics. Since CPT first described by Hatzoecher [1] at the beginning of the 18th century, a great number of treatment approaches and different surgical procedures have been

proposed. Until today, none of these methods have proved to be ideal to achieve and then maintain bony union, while simultaneously providing a functional extremity. Even if union has been achieved, in many cases further multiple operations for the corrections of subsequent deformities of the extremity are still required. Because amputation is frequently indicated after several failed surgical procedures, early amputation has been proposed as an alternative [2].

Free vascularized fibular graft (FVFG) has been use with great success in the management of difficult orthopedic problems since 1975 [8]. The great attraction of this method is that allows aggressive resection of the dysplastic tibial bone and the surrounding pathological tissue, and its replacement with a vascularized bone with

normal healing potential. Primary bone lengthening could also be achieved at the same time.

Marked hypertrophy of the transferred fibula occurs early after the procedure in response to the increased stress.

Case Report

A 5 years old boy complained unable to walk, difficulty in active and passive movement of the lower extremity and then was diagnosed as Congenital Pseudarthrosis of the left tibia as seen in Figure 1. When he was 1.5 year-old, the patient had performed closed reduction and long leg cast application for 2 months. Unfortunately, the bone was bowing. Half a year later the patient underwent Open Reduction Internal Fixation (ORIF) using plate and screw for a year period, then underwent re ORIF and reconstruction procedure when he reached 3 years old with unsatisfying result.

After operation was performed by previous orthopedic surgeon. Finally, patient came to our institution and got overall evaluation, we decided to do Free Vascularized fibular graft, re ORIF with intramedullary Kirschner wire and long leg cast application. In Figure 2 we can see the affected tibia is exposed through a longitudinal anteromedial incision, complete excision of the pathologic tissue is required for recurrence prevention. The fibula graft is inserted into the tibial defect. Microsurgical techniques are used for artery and vein end-to-end anastomoses.

A month follow up showed callus formation, then Patellar Tendon Bearing and Partial Weight Bearing were applied. After 5 months follow up, ORIF with intramedullary Kirschner wire provided stability, and acceptable alignment resulted in bony union.

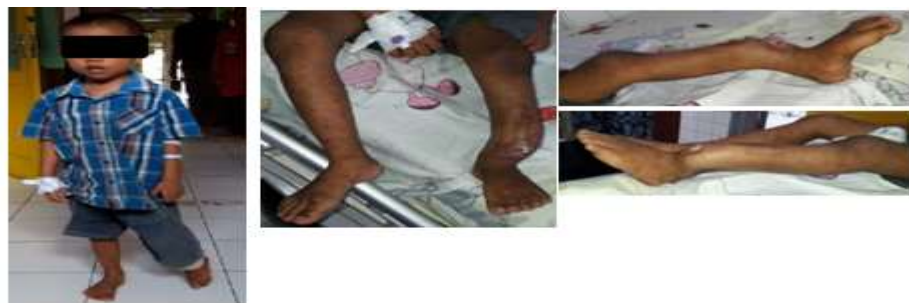

Figure 1: Pre-operative clinical and serial xray evaluation before the FVFG

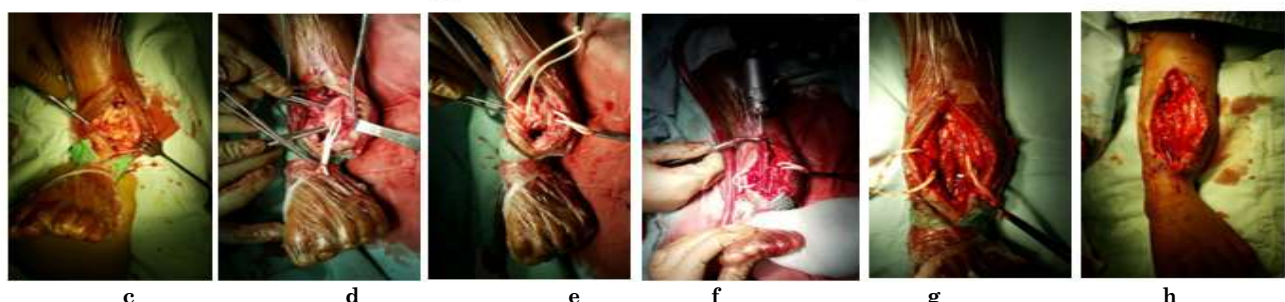
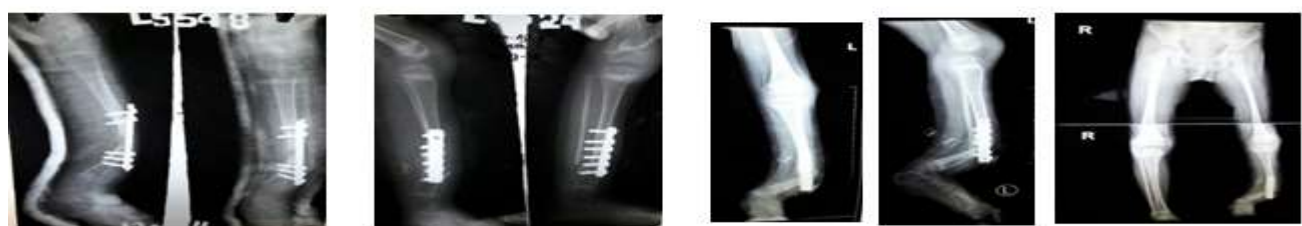


Figure 2: Clinical picture during the operation. a). tam plating of the fibular graft, b).When the fibula expose, c). Fibrous of the affected site, d-e).Peroneal artery and vein anastomosis, f).Intramedullary K-wire fixation the bone graft to the affected site tibia, g-h).Clinical post operative

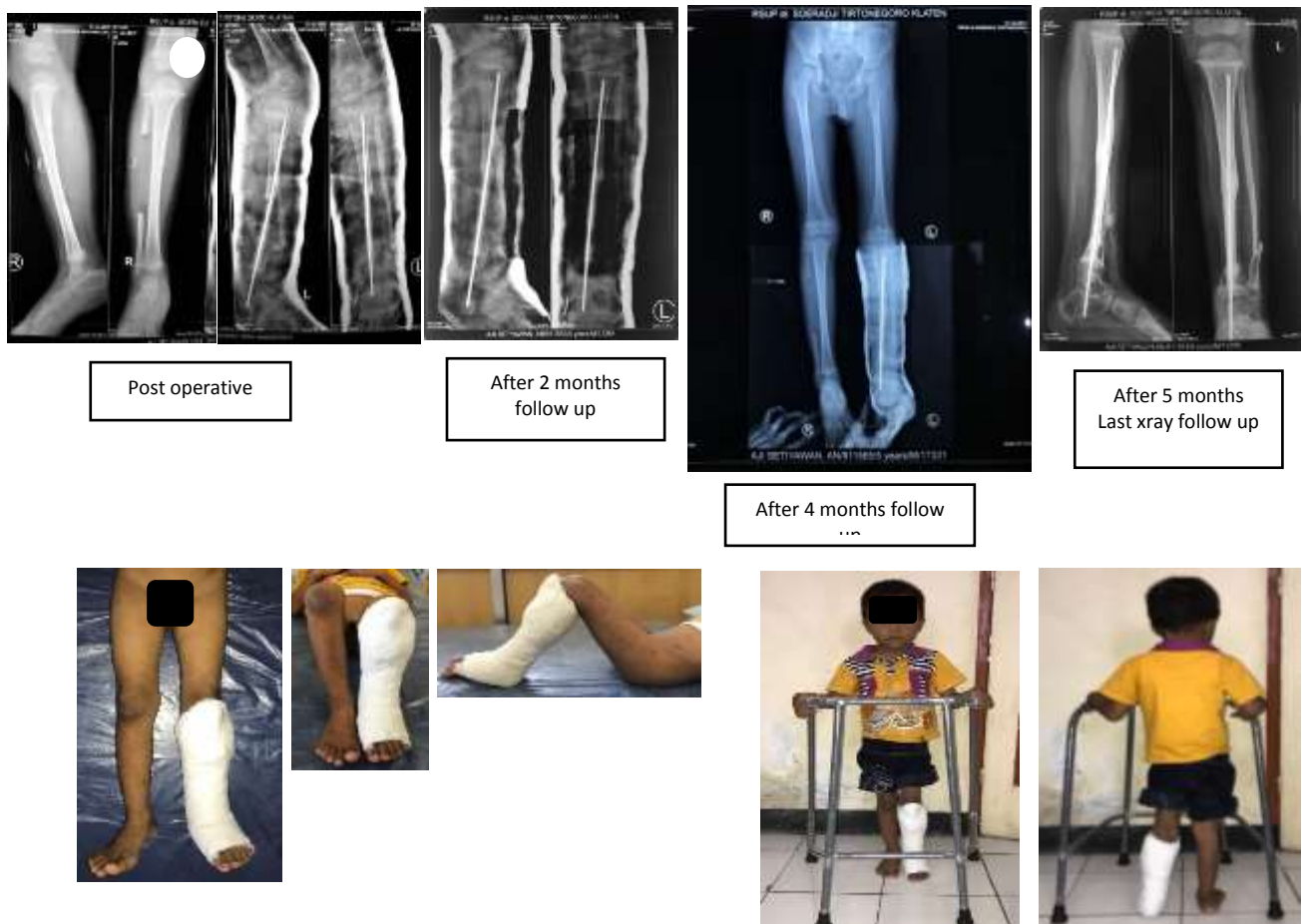


Figure 3: Post-operative xray resulted bony union, from clinically can standing and walk

Discussion

The natural history of CPT is recalcitrant nonunion, atrophy of the bone and the leg, progressive LLD and deformity, and recurrent refracture even after union is achieved in surgery. The primary objective of treatment for CPT is to obtain union. The secondary objective is to maintain union. In addition, many associated deformities of length and angulation should be addressed in the comprehensive management of CPT. Therefore, unless all patients have reached skeletal maturity, the refracture rate reported is always lower than actual [4]. The main surgical options for treatment of CPT are vascularized fibular grafting, IM stabilization, external fixation with a circular frame, and amputation [5].

Electric stimulation has also been studied. Paley et al [6] presented a report of 15 patients who had 16 tibiae with congenital pseudarthrosis. The mean patient age was 8 years, the rate of union was 94% in 15 patients with Illizarov frames, refracture occurred in five tibiae (31%) and the mean follow-up duration was 4 years. Boero et al [7] presented a report of 21 patients with neurofibromatosis treated with Illizarov

frames. The mean patient age was 8.8 years. The primary union rate was achieved in 17 of 21 (81%) patients. Refracture occurred in four of the 17 patients (19%), and the minimum follow up duration was 2 years. The European Paediatric Orthopaedic Society (EPOS) multicenter study [8] of 340 patients with CPT reported a 75% healing rate achieved with Illizarov external fixation and recommended the use of prophylactic IM rodding to prevent refracture. In a series of 17 tibiae with CPT treated by Paley and Herzenberg, half of which were followed up to skeletal maturity, the mean patient age was 8 years, union was obtained in 100% of the patients, and refracture occurred in 68% when the Illizarov device without IM rodding was used [9].

When IM rodding was combined with external fixation, the refracture rate dropped to 29%. Ohnishi et al [10] reported 73 cases that were treated with different treatment protocols: 26 with Illizarov fixation, 25 with vascularized fibular grafting, seven with the combination of the previous two techniques, six with IM rodding combined with free bone grafting, five with plating and grafting, and

the remaining four with different treatment protocols.

The average patient age was 5 years. Union was achieved in all patients treated with Ilizarov fixation (four experienced refracture), 22 of 25 (88%) patients treated with free vascularized fibular grafting (one experienced refracture), and all patients treated with both fibular grafting and Ilizarov fixation. IM rodding is an alternative treatment option to achieve and maintain union, although the reported results are variable. Joseph and Mathew [11] reported 14 skeletally immature patients treated with IM rodding and double on lay autogenous bone grafting from the opposite tibia. The mean patient age was 4.5 years, the union rate was 86%, the mean follow up duration was 3 years, and the refracture rate was 21% (three of 14).

Johnston [12] reported on 23 patients treated with different techniques of IM rodding and grafting. The mean patient age was 2 years 4 months, the mean follow up duration was 9 years, the primary union rate was 87%, and 13% had persistent nonunion and bad outcomes. The author noted that two important factors for the best outcome for patients with CPT were perfect limb alignment and the use of IM rods to achieve union, prevent refracture, and maintain alignment. Kim and Weinstein [13] reported on 11 patients with 12 tibiae with congenital pseudarthrosis treated with IM rodding and free bone grafting. The mean patient age at the time of the index operation was 2.5 years.

Four of the 11 patients healed after the primary index operation. Two of the four experienced refracture; one healed with a long lower limb cast, and the other healed after the index operation was repeated. The other seven did not heal after the index operation. Four of them achieved healing after undergoing multiple surgical procedures (one required free vascularized fibular grafting, and three required repeated IM rodding and grafting; one of the three had nonunion, one needed Syme amputation, and one had a failed Sofield procedure).

Healing could not be achieved in the other three patients (two underwent below-knee amputation, and one had persistent nonunion at the latest follow up visit). Kim concluded that IM rodding provides more predictable results in cases of late-onset pseudarthrosis.

Dobbs et al [14] reported the long-term follow up (mean follow up duration, 14.2 years) of 21 patients with CPT (mean patient age, 5.1 years) treated with IM rodding and bone grafting. The primary union rate was 86% (18 patients), and three patients required additional bone grafting to achieve union. Twelve patients (57%) experienced refracture, and five (24%) required amputation. Free vascularized fibular grafting had been described by several authors as a good option for achieving union in patients with CPT, although it is associated with many drawbacks, including nonunion, refracture, and recurrent nonunion at one site of the graft end. Angular deformity of the affected tibia (valgus or anterior bowing) has been reported. The deformities usually are progressive and require further treatment.

Donor site morbidity, such as progressive ankle valgus with proximal migration of the distal fibula, is another problem associated with vascularized fibular grafting. The tibiofibular synostosis can only delay but not prevent ankle valgus [15]. Free vascularized fibular graft procedure was applied as a gold standard therapy for CPT using surgical loupe in operating theater based on the literatures. The fibula has been long recognized as an attractive choice for vascularized bone grafting procedures, because this technique is essential to ensure the required arterial and venous anastomoses and long-term graft viability. The union rate was 81% for vascularized bone grafting.

On this case radiographic union scale in tibial fracture (RUST) score is [6]. It is important to keep the goal of treatment in mind: the achievement of a healed, functional, and well align extremity when the skeletal reached its maturity using fewer operations as possible. CPT is an almost unpredictable clinical entity with numerous complications and not always favorable functional outcome, several prognostic factors have been proposed. Among them, the type of pseudarthrosis, the age at which union is achieved, the rapid resorption of the graft used to bridge the defect, and the age of onset are critical to the success of treatment [16].

The type of pseudarthrosis is considered one of the most important parameters that may affect the outcome and the management algorithm. The goals of surgical management include treatment of the established

pseudarthrosis and prevention of the fracture. During treatment selection, several problems associated with tibia pseudarthrosis, such as limb-length discrepancy, severe deformity, disuse atrophy of the bone, involvement of the ipsilateral fibula, and history of previous surgeries, should be taken into consideration. To overcome these difficulties several treatment modalities with various results have been used, including bone electric stimulation, intramedullary fixation, vascularized or non-vascularized grafts, Ilizarov technique, and recently recombinant bone morphogenetic proteins (BMP-2, BMP-7) [17]. Free vascularized fibula transplant remains a valuable method for treating CPT. It combines thorough excision of the pathologic

tissue and primary lengthening of the tibia. By bringing its own blood supply and increasing the blood flow in the distal tibial epiphysis, free vascularized fibula further enhances limb lengthening. Despite of the relatively high-complication rate, FVFG should be considered as a primary treatment option for CPT.

Conclusion

This case showed good result appeared as bone union after free vascularized fibular graft procedure in congenital pseudarthrosis tibia case. However, even achieving union of pseudarthrosis is not enough for the resolution of the disease. This is only half of the problem; the other half is to maintain union [18, 22].

References

1. Boyd HB, Sage FP (1958) Congenital pseudarthrosis of the tibia. *J. Bone Joint Surg. Am.*, 40:1245-1270.
2. Andersen KS (1973) Radiological classification of congenital pseudarthrosis of the tibia. *Acta Orthop. Scand.*, 44:719-727.
3. Taylor GI, Miller GDH, Ham FJ (1975) The free vascularized bone graft. A clinical extension of microvascular techniques. *Plast Reconstr. Surg.*, 55:533-544.
4. Morrissy RT (1982) Congenital pseudarthrosis of the tibia: factors that affect results. *Clin Orthop. Relat. Res.*, 166:21-7.
5. McCarthy RE (1982) Amputation for congenital pseudarthrosis of the tibia: indications and techniques. *Clin Orthop. Relat. Res.*, 166:58-61
6. Paley D, Catagni M, Argnani F, Prevot J, Bell D, Armstrong P (1992) Treatment of congenital pseudoarthrosis of the tibia using the Ilizarov technique. *Clin Orthop. Relat. Res.*, 280:81-93.
7. Boero S, Catagni M, Donzelli O, Facchini R, Frediani PV (1997) Congenital pseudarthrosis of the tibia associated with neurofibromatosis-1: treatment with Ilizarov's device. *J. Pediatr. Orthop.*, 17:675-84
8. Grill F, Bollini G, Dungal P, et al (2000) Treatment approaches for congenital pseudarthrosis of tibia: results of the EPOS multicenter study: European Paediatric Orthopaedic Society (EPOS). *J. Pediatr. Orthop. B.*, 9:7589.
9. El-Rosasy MA, Paley D, Herzenberg JE (2001) Ilizarov techniques for the management of congenital pseudarthrosis of the tibia (PhD Thesis). Tanta, Egypt: Tanta University Press.
10. Ohnishi I, Sato W, Matsuyama J, et al (2005) Treatment of congenital pseudarthrosis of the tibia: a multicenter study in Japan. *J. Pediatr. Orthop.*, 25:219-24.
11. Joseph B, Mathew G (2000) Management of congenital pseudarthrosis of the tibia by excision of the pseudarthrosis, onlay grafting, and intramedullary nailing. *J. Pediatr. Orthop. B.*, 9:16-23.
12. Johnston CE II (2002) Congenital pseudarthrosis of the tibia: results of technical variations in the Charnley-Williams procedure. *J. Bone Joint Surg Am.*, 84:1799-810
13. Kim HW, Weinstein SL (2002) Intramedullary fixation and bone grafting for congenital pseudarthrosis of the tibia. *Clin Orthop. Relat. Res.*, 405:250-7.
14. Dobbs MB, Rich MM, Gordon JE, Szymanski DA, Schoenecker PL (2004) Use of an intramedullary rod for treatment of congenital pseudarthrosis of the tibia: a long-term follow up study. *J. Bone Joint Surg. Am.*, 86:1186-1197
15. Weiland AJ, Weiss AP, Moore JR, Tolo VT (1990) Vascularized fibular grafts in the

- treatment of congenital pseudarthrosis of the tibia. *J. Bone Joint Surg. Am.*, 72:654-62.
16. Delgado-Martinez AD, Rodriguez-Mercha N, Olsen B (1996) Congenital pseudarthrosis of the tibia. *Int. Orthop.*, 20:192-199.
 17. Romanus B, Bollini G, Dungal P, Fixsen J, Grill F, Hefti F, Ippolito E, Tudisco C, Wientroub S (2000) Free vascular fibular transfer in congenital pseudoarthrosis of the tibia: Results of the EPOS multicenter study. *J. Pediatr. Orthop. B* (9):90-93.
 18. Courney O'D, James F, et al (2017) Congenital Pseudoarthrosis of the Tibia, www.JBJS.com, 5: 4.
 19. Raj Kumar M, et al (2013) Congenital Pseudoarthrosis of the Tibia : A Case Report, www.iosrjournals.org, 21-22
 20. Donald, Waters, MD, et al (2015) Free Vascularized Fibula Grafting: principles, techniques and applications in pediatric orthopaedic, Harvard Medical School.
 21. Jagdish Patwa, et al (2013) A short series of congenital pseudoarthrosis tibia, Departement of Orthopedics, Sumandeeep Vidyapeeth (institute), Dhiraj Hospital, India.
 22. M Bumbasivevic, et al (2014) Free vascularized fibular graft in orthopedics, School of medicine, Clinic of Orthopedic Surgery and Traumatology, University of Belgrade, Serbia.